

ACLAND'S VIDEO ATLAS OF HUMAN ANATOMY

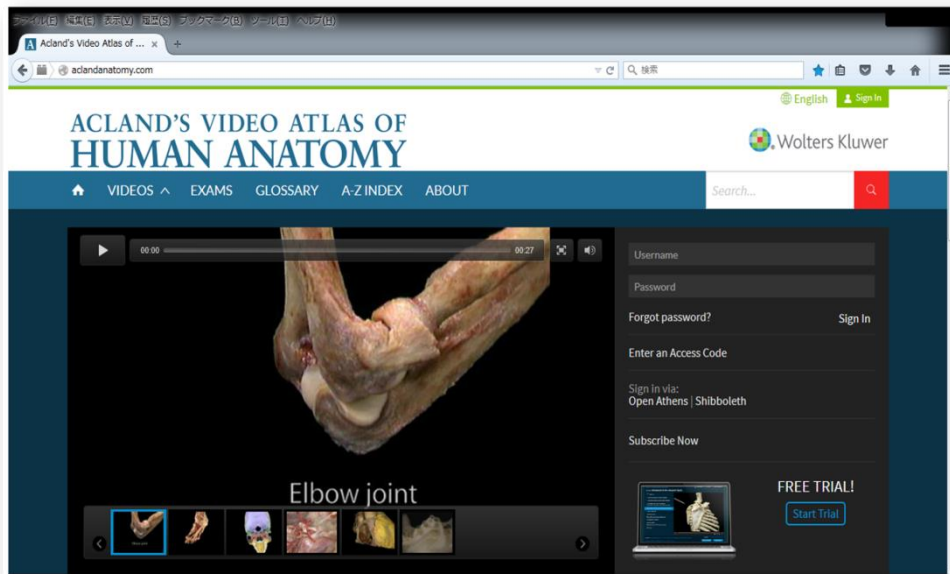




Wolters Kluwer

Acland's Video Atlas of Human Anatomy

肉眼解剖教材の決定版! 3次元ビデオ画像



約200体のご遺体を用いて撮影された肉眼解剖のナレーションガイド付きビデオ

解剖学実習の教育と学生の自習をサポート

スマートフォンやタブレットからもアクセス可能

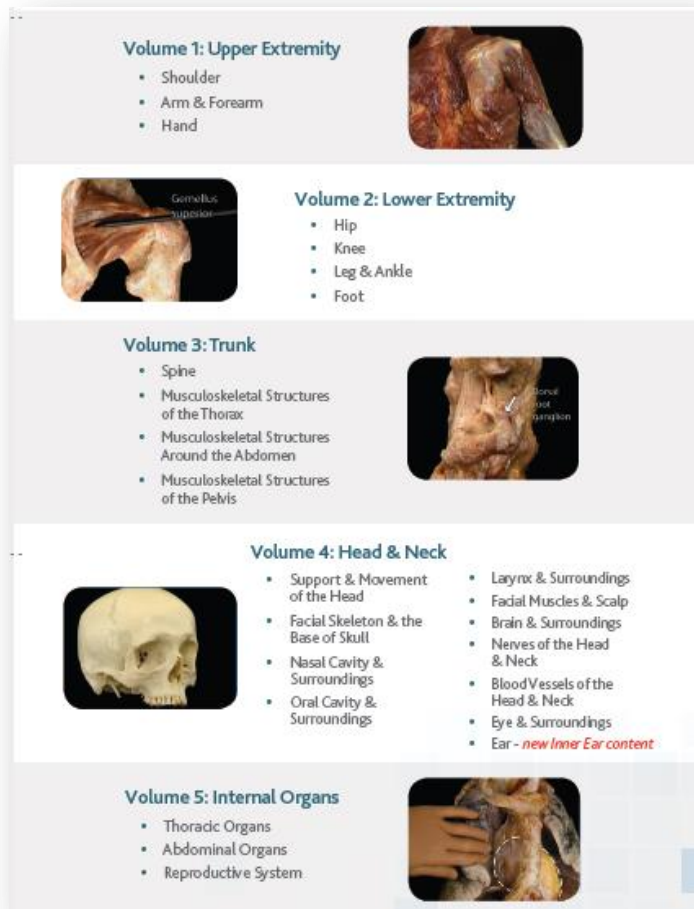判り易いインデックス

復習や試験準備の為のEXAMモード



Wolters Kluwer

製品の特徴



ヒト全身の肉眼解剖3次元ビデオ

- 上肢(筋骨格系を含む)
- 下肢(筋骨格系を含む)
- 胴体(心血管&呼吸器を含む)
- 頭部・頸部(神経系を含む)
- 内臓(生殖システムを含む)

University of Louisville School of Medicineの
Robert (Bob) Acland 博士と彼のチームにより開
発された328点、計15時間を越える、ナレーション解
説付きビデオ

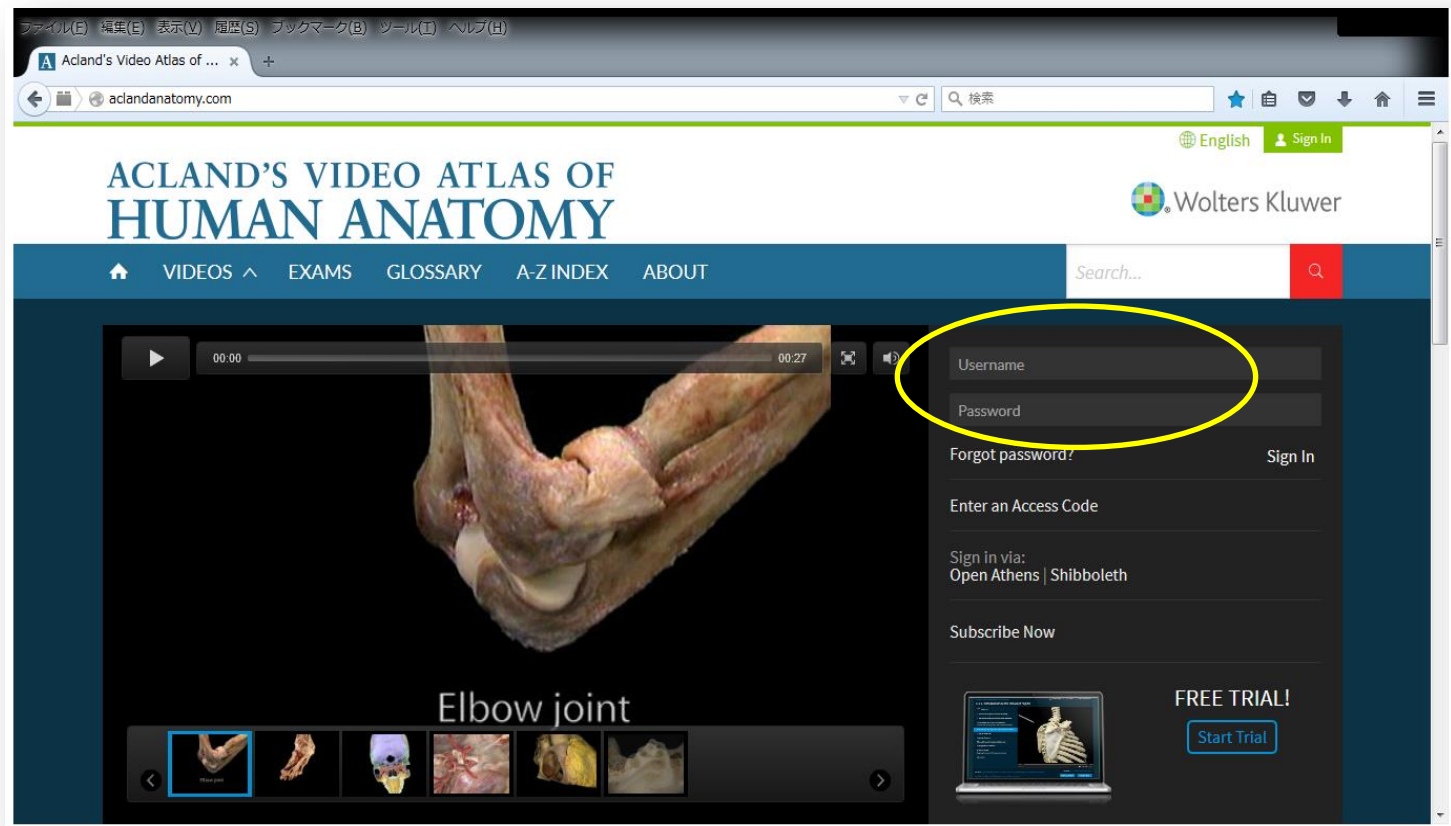
乾燥などによる不自然な外観や組織変色をさせない保存技術を用いた、生体組織の色・組織、膜の質感や動きなどを、正確に反映した3Dビデオ画像

筋肉・腱・関節等の運動性構造と機能についても、
動画で詳述



Wolters Kluwer

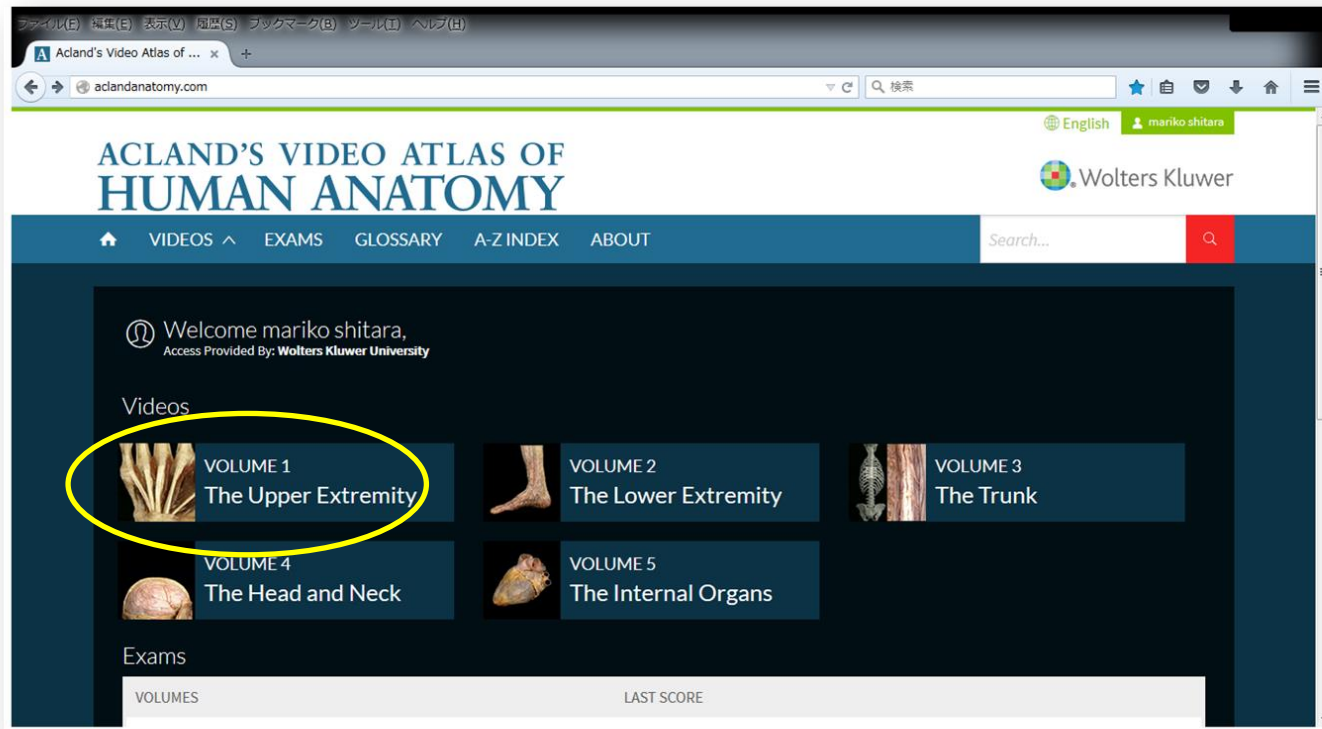
ログイン画面: IP認証でお使いいただけます
最初にPersonal Accountの設定をお願いします
<http://www.aclandanatomy.com>



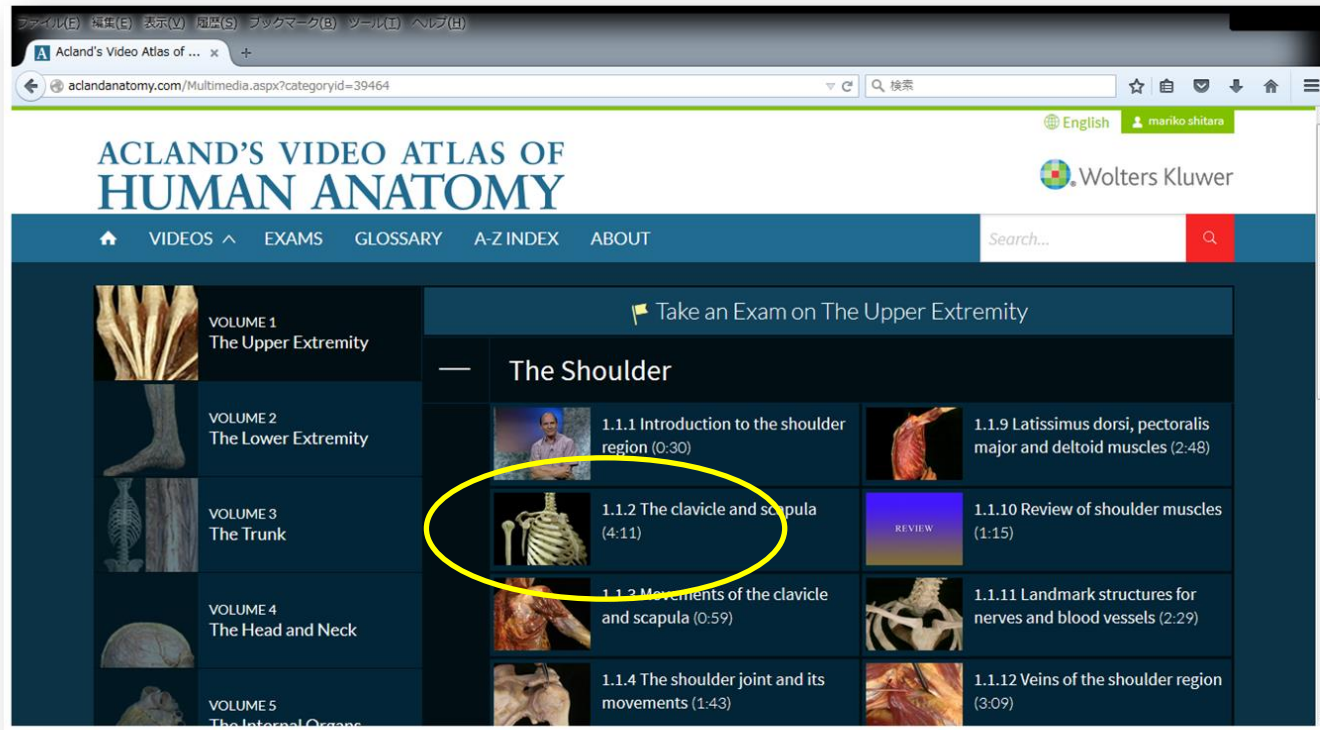


Wolters Kluwer

VIDEOS トップ画面:
volume 1: Upper Extremityを選択してみました



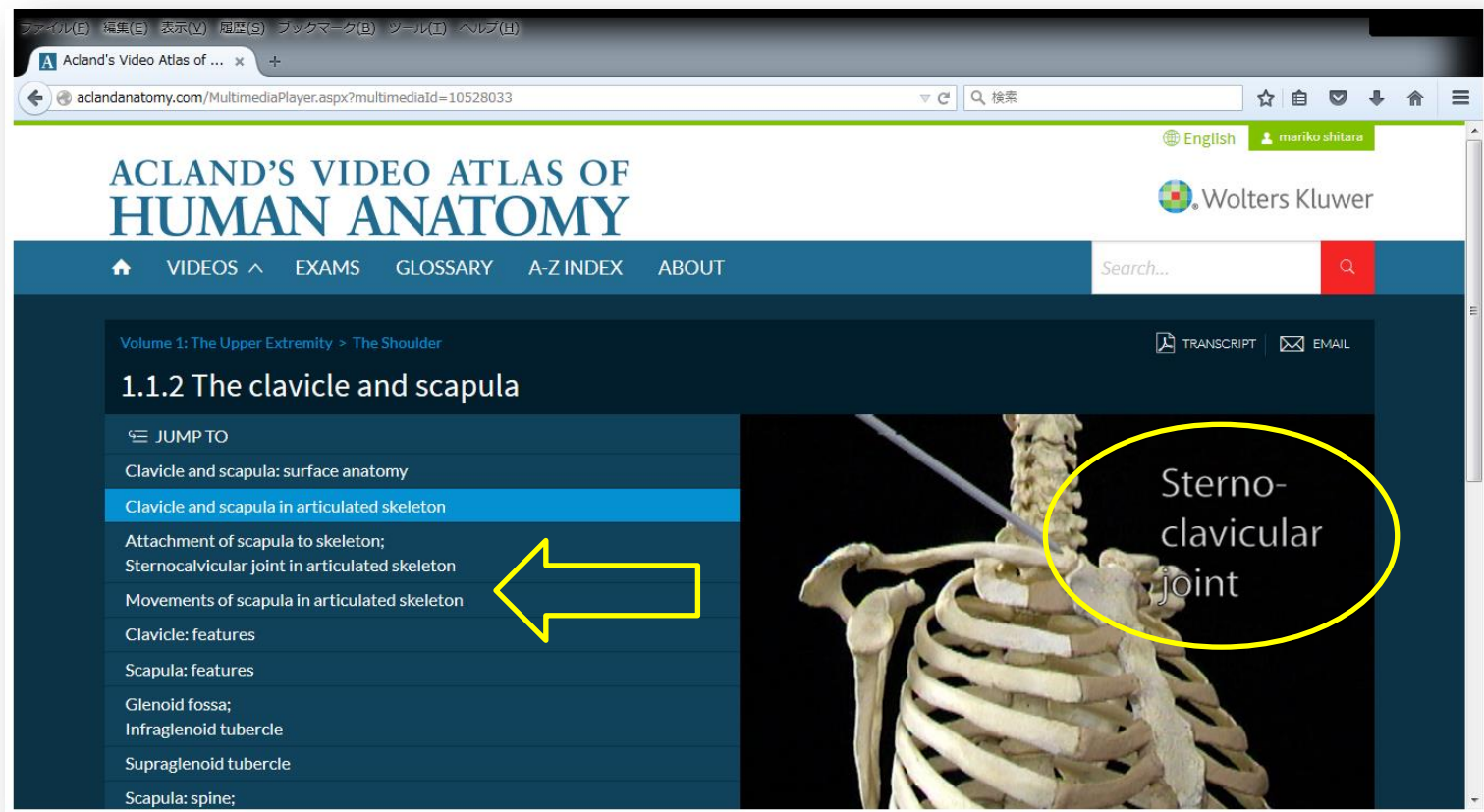
1.1.2のビデオを選択: メニューに画像が入って判りやすくなりました





Wolters Kluwer

Clavicle and scapula in articulated skeletonを選択
ビデオがスタートすると、Robert (Bob) Acland 博士のナレーションと共に、
各部位の名称が表示されます。





Wolters Kluwer

Transcriptをクリックすると、ナレーション内容をPDFファイルで取得できます。

ブラウザのアドレスバー: aclandanatomy.com/MultimediaPlayer.aspx?multimediaId=10528033

ナビゲーションメニュー: HOME VIDEOS ^ EXAMS GLOSSARY A-Z INDEX ABOUT

検索バー: Search...

Volume 1: The Upper Extremity > The Shoulder

1.1.2 The clavicle and scapula

TRANSCRIPT EMAIL

JUMP TO

- Clavicle and scapula: surface anatomy
- Clavicle and scapula in articulated skeleton
- Attachment of scapula to skeleton; Sternoclavicular joint in articulated skeleton
- Movements of scapula in articulated skeleton
- Clavicle: features
- Scapula: features
- Glenoid fossa; Infraglenoid tubercle
- Supraglenoid tubercle
- Scapula: spine; Supraspinous and infraspinous fossa
- Acromion
- Coracoid process
- Glenoid labrum

ビデオ内の見たい場所にジャンプできます

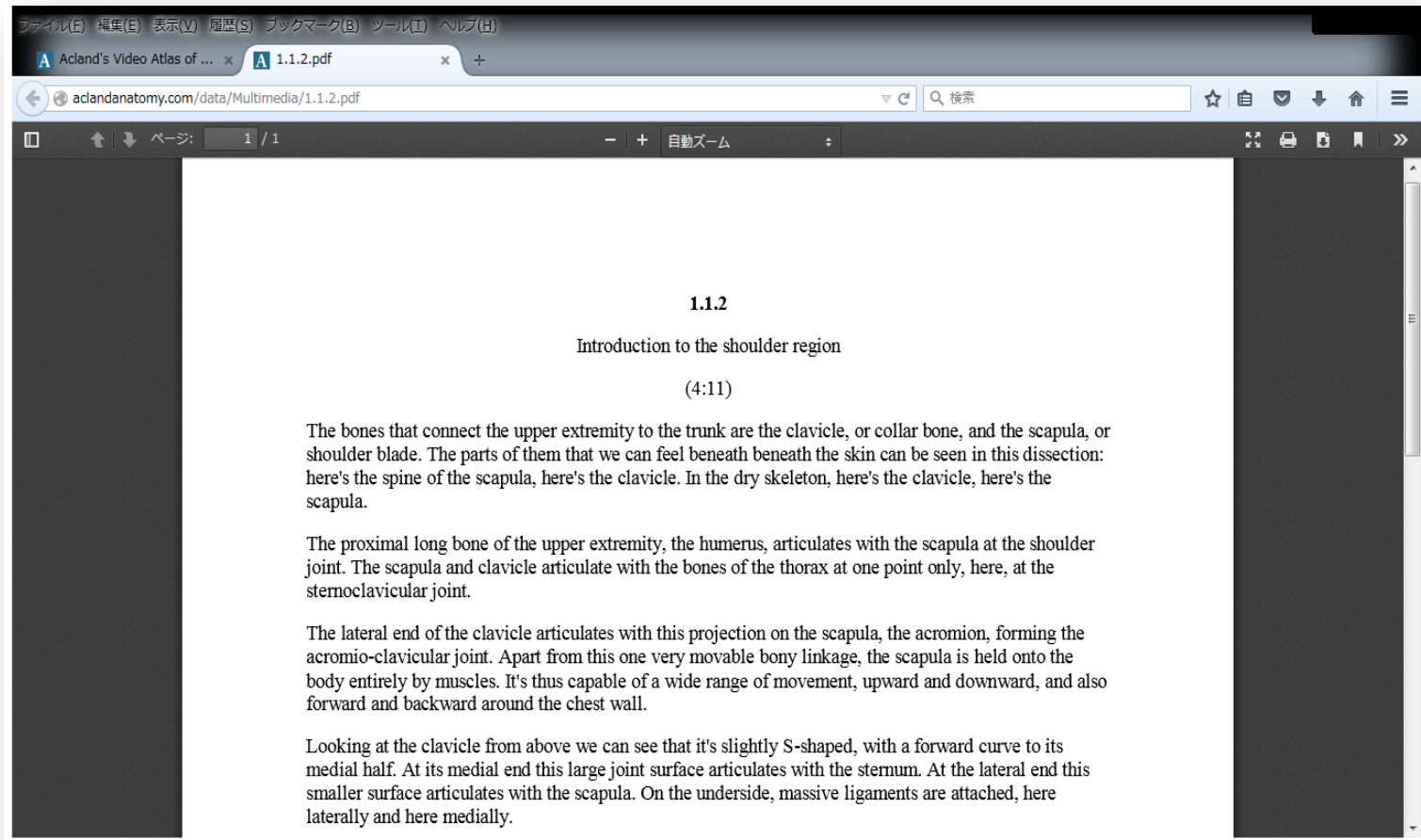
Trapezoid ligament

Conoid ligament

ビデオ機能



ビデオのナレーション原稿は、PDFファイルにダウンロードできます





Wolters Kluwer

キーワード検索

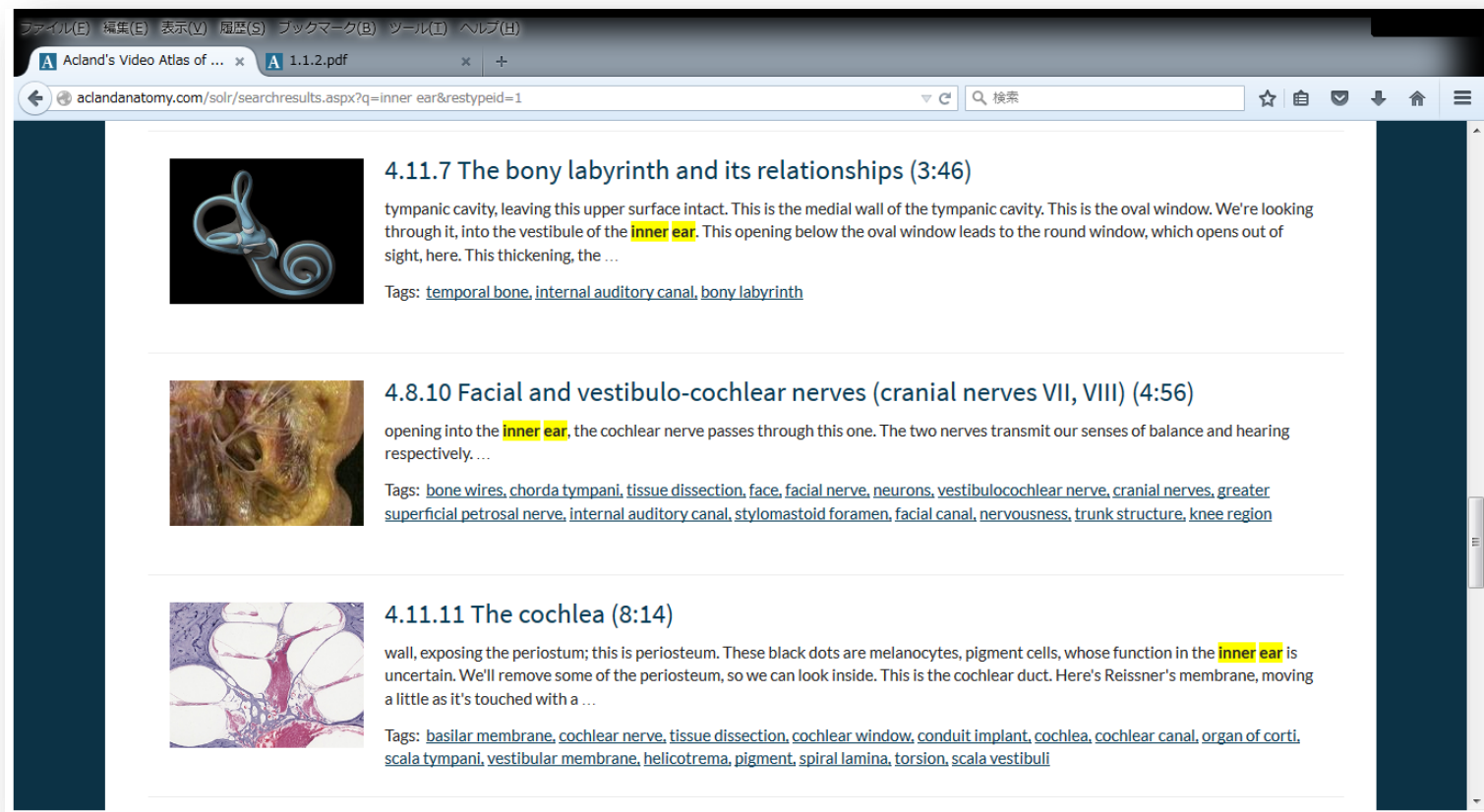
キーワード検索例: Inner Ear と入力

The screenshot shows a web browser window with the URL aclandanatomy.com/Multimedia.aspx?categoryid=39464. The page title is "ACLAND'S VIDEO ATLAS OF HUMAN ANATOMY". The navigation bar includes links for HOME, VIDEOS, EXAMS, GLOSSARY, A-Z INDEX, and ABOUT. A search bar in the top right corner contains the text "inner ear" and is highlighted with a yellow circle. Below the navigation bar, there is a section titled "Take an Exam on The Head and Neck" with a list of topics: "Support and Movement of the Head", "The Facial Skeleton and Base of Skull", "The Nasal Cavity and its Surroundings", "The Oral Cavity and its Surroundings", "The Larynx and its Surroundings", and "The Facial Muscles and the Scalp". On the left side, there are five volume thumbnails: "VOLUME 1 The Upper Extremity", "VOLUME 2 The Lower Extremity", "VOLUME 3 The Trunk", "VOLUME 4 The Head and Neck", and "VOLUME 5 The Internal Organs".



キーワード検索

検索結果の表示: Inner Ear



4.11.7 The bony labyrinth and its relationships (3:46)

tympanic cavity, leaving this upper surface intact. This is the medial wall of the tympanic cavity. This is the oval window. We're looking through it, into the vestibule of the **inner ear**. This opening below the oval window leads to the round window, which opens out of sight, here. This thickening, the ...

Tags: [temporal bone](#), [internal auditory canal](#), [bony labyrinth](#)

4.8.10 Facial and vestibulo-cochlear nerves (cranial nerves VII, VIII) (4:56)

opening into the **inner ear**, the cochlear nerve passes through this one. The two nerves transmit our senses of balance and hearing respectively. ...

Tags: [bone wires](#), [chorda tympani](#), [tissue dissection](#), [face](#), [facial nerve](#), [neurons](#), [vestibulocochlear nerve](#), [cranial nerves](#), [greater superficial petrosal nerve](#), [internal auditory canal](#), [stylomastoid foramen](#), [facial canal](#), [nervousness](#), [trunk structure](#), [knee region](#)

4.11.11 The cochlea (8:14)

wall, exposing the periostum; this is periosteum. These black dots are melanocytes, pigment cells, whose function in the **inner ear** is uncertain. We'll remove some of the periosteum, so we can look inside. This is the cochlear duct. Here's Reissner's membrane, moving a little as it's touched with a ...

Tags: [basilar membrane](#), [cochlear nerve](#), [tissue dissection](#), [cochlear window](#), [conduit implant](#), [cochlea](#), [cochlear canal](#), [organ of corti](#), [scala tympani](#), [vestibular membrane](#), [helicotrema](#), [pigment](#), [spiral lamina](#), [torsion](#), [scala vestibuli](#)



Wolters Kluwer

「Glossary」で、解剖用語を確認できます

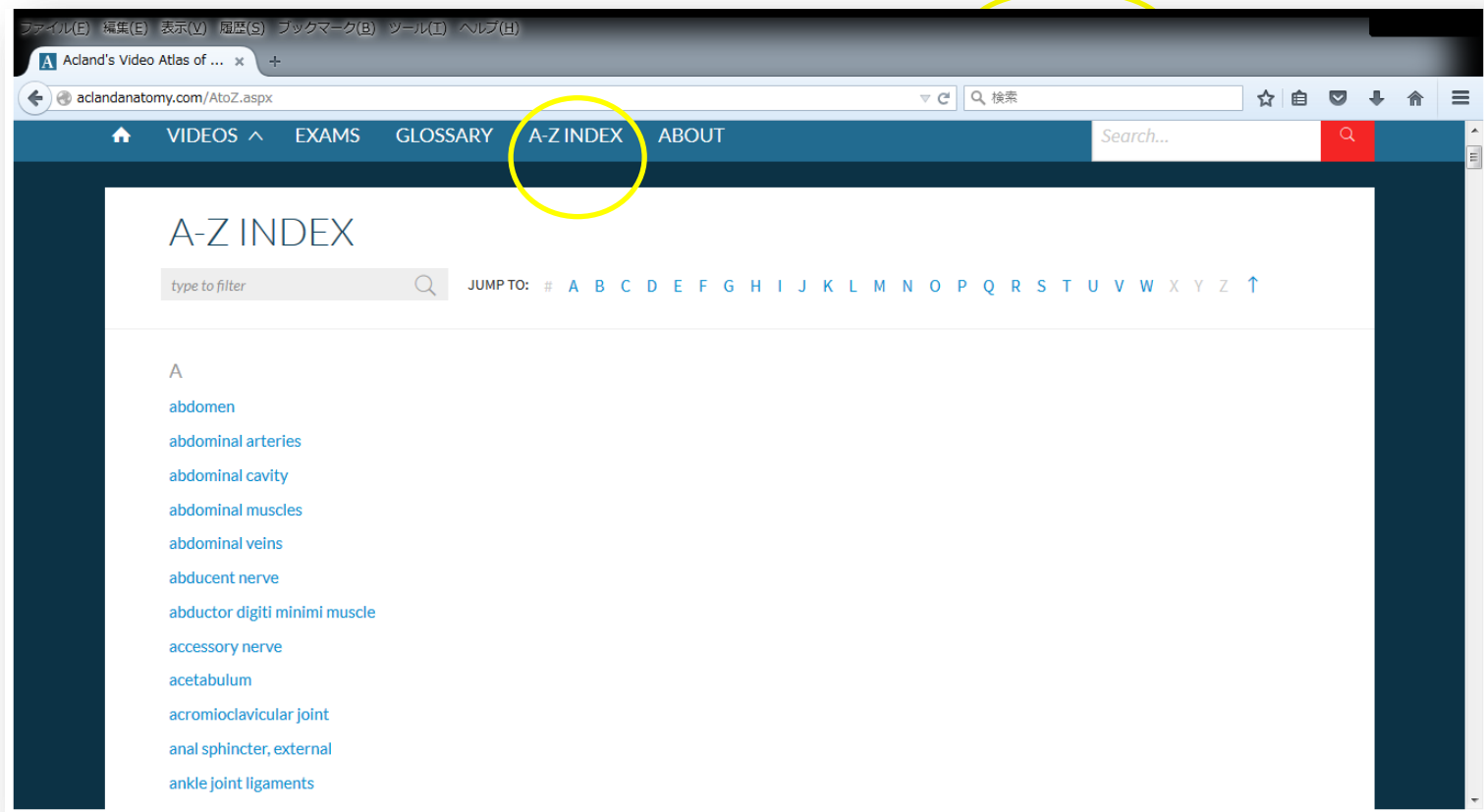
The screenshot shows a web browser displaying the 'Glossary' page of 'Acland's Video Atlas of Human Anatomy'. The browser's address bar shows 'aclandanatomy.com/Glossary.aspx'. The website's header includes the title 'ACLAND'S VIDEO ATLAS OF HUMAN ANATOMY' and the Wolters Kluwer logo. A navigation bar contains links for 'HOME', 'VIDEOS', 'EXAMS', 'GLOSSARY' (which is circled in yellow), 'A-Z INDEX', and 'ABOUT'. Below the navigation bar, the 'Glossary' section is titled, followed by an introductory paragraph: 'Many anatomic structures are still known by names given when Greek, Arabic and Latin were languages of learning. There are no accepted translations for most anatomic names, so these interesting links with the past remain in service.' Below this is a search bar with the placeholder 'type to filter' and a 'Jump to:' section with a list of letters from A to Z. The main content area displays a table of anatomical terms starting with 'A'.

A		
Abduct	LATIN	<i>ab, away + ducere, pull.</i>
Acetabulum	LATIN	<i>actum, vinegar + abrum, holder. Small cup for vinegar, hence any small cup.</i>
Adduct	LATIN	<i>ad, towards + ducere, pull.</i>
Adrenal	LATIN	<i>ad, toward + ren, kidney.</i>
Ala (alar)	LATIN	<i>ala, wing.</i>
Alveolus (alveolar)	LATIN	<i>alveolus, small compartment.</i>



Wolters Kluwer

「A-Z Index」で、アルファベット順に表示





Wolters Kluwer

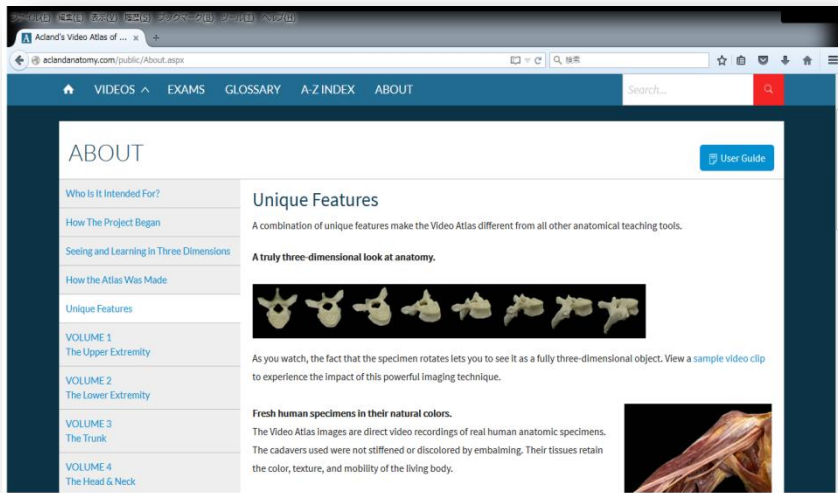
「Exams」をクリックすると、理解度をチェックできます
復習モードと試験モードを選べます

The screenshot shows the website interface for ACLAND'S VIDEO ATLAS OF HUMAN ANATOMY. The browser address bar shows the URL: `aclandanatomy.com/Exams/ExamVolume.aspx?categoryId=39468`. The navigation menu includes: HOME, VIDEOS, EXAMS (highlighted with a yellow circle), GLOSSARY, A-Z INDEX, and ABOUT. The main content area is titled "Volume 4: The Head and Neck". Below this, there is a section for "LAST EXAM TAKEN" with a circular progress indicator showing "60" and "NOT FINISHED". A "Start a New Exam" button is visible. A modal window titled "Start Exam: Volume 4: The Head and Neck" is open, showing options for "Experience" (Time Me), "Review" (Check my answers immediately or Review my answers after the exam), and "Questions" (Target questions I got wrong). A "Start Exam" button is at the bottom of the modal.



Wolters Kluwer

ご利用環境



アクセス数: 無制限アクセス

契約形態: 年間契約(購読形態)

認証: IP認証 または、ID/PW

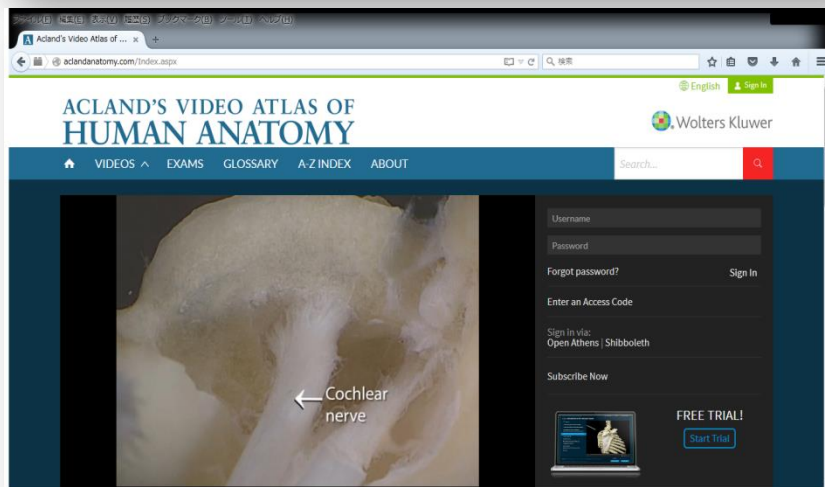
対応機種: PC, スマートフォン、タブレット
(モバイル・バージョンはモバイル・デバイス上のブラウザに依存します。)

ビデオ画像からのイメージ画像(スクリーンショット等)を授業で、お使いいただく事が出来ません。

不定期な情報更新があります((最新更新:内耳)

ビデオ画像に表示される文字表示のON/OFF機能はありません

Pathology/Diseased/Abnormal anatomy情報は含まれていません





Wolters Kluwer

[お問い合わせ先]

WOLTERS KLUWER
HEALTH LEARNING, RESEARCH & PRACTICE事業部
〒108-0073 東京都港区三田1-3-31
フォーキャスト三田ビル5階

TEL:(03) 5427-1950
EMAIL: OVID-JAPAN@WOLTERSKLUWER.COM